

## Revealing trauma

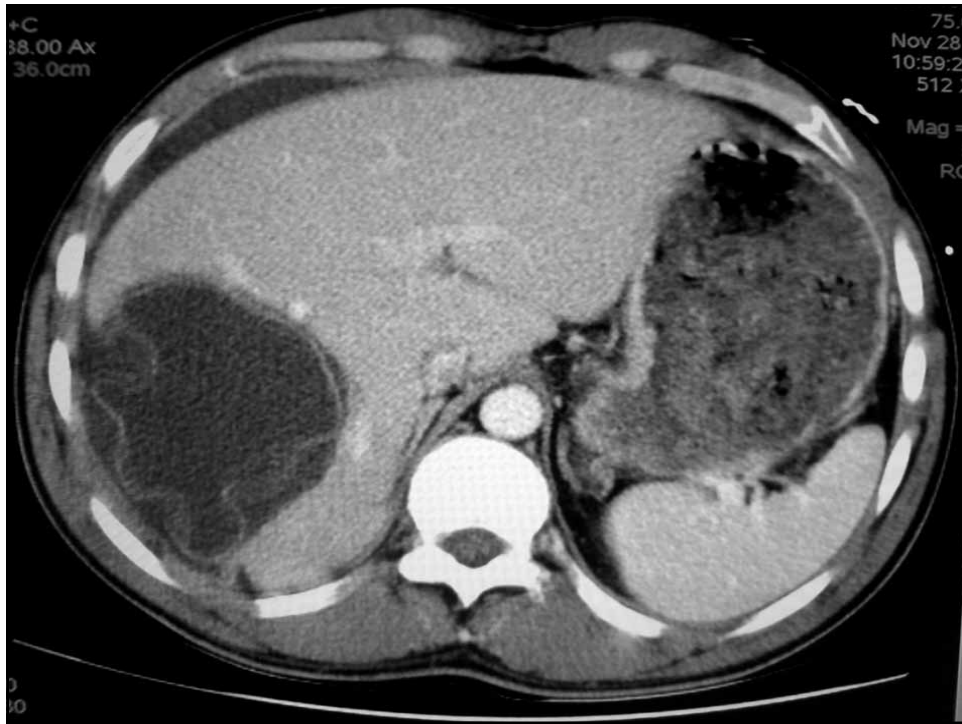
M. Mino, N. Troillet, V. Bettschart,  
N. Letovanec, F. Bally



## M. AF 31 years

28.11.2006:

- Motorbike accident (45km/h).
- GCS 15/15. BP 132/56 mmHg, CF 70/min.
- Abdominal pain in the right upper and lower quadrants.
- Lesser wounds (left eyebrow, upper lip).  
Broken teeth



A ruptured echinococcal cyst was suspected

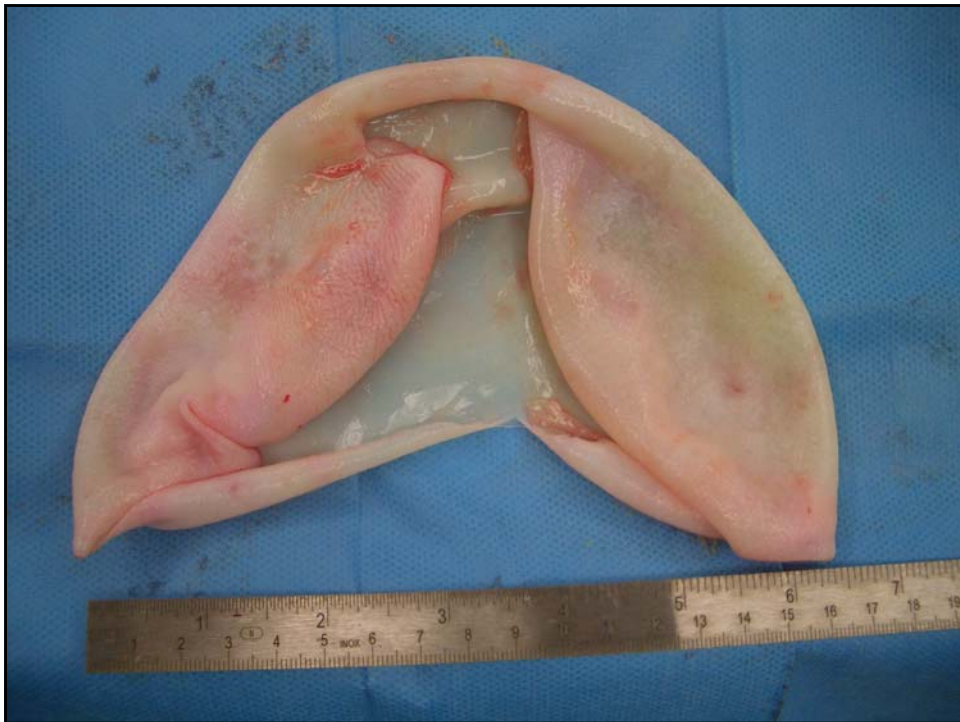What would you do ?

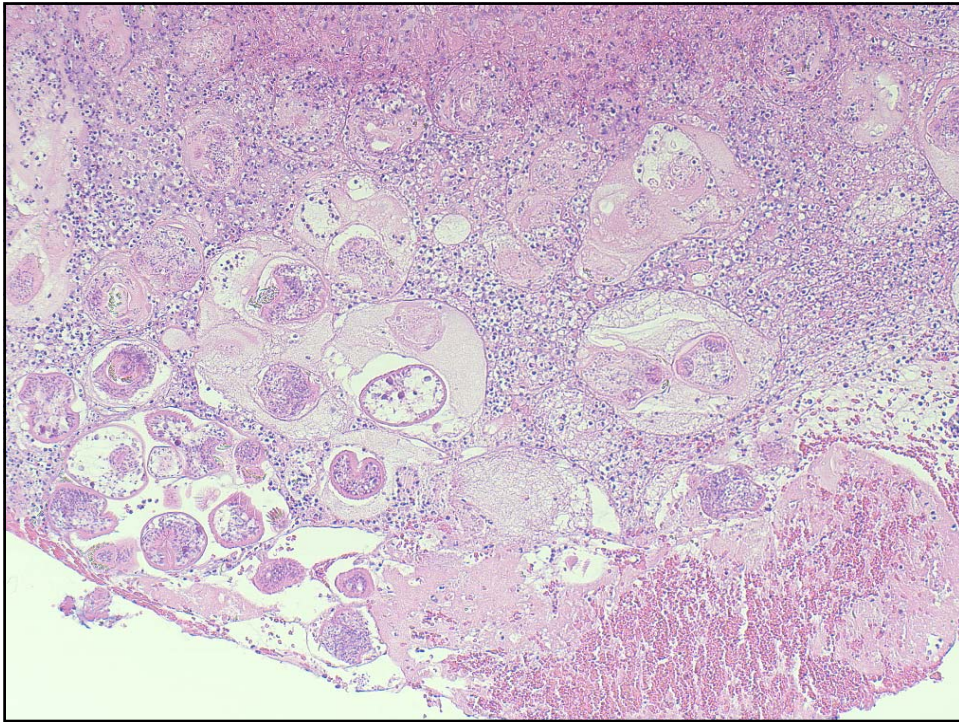
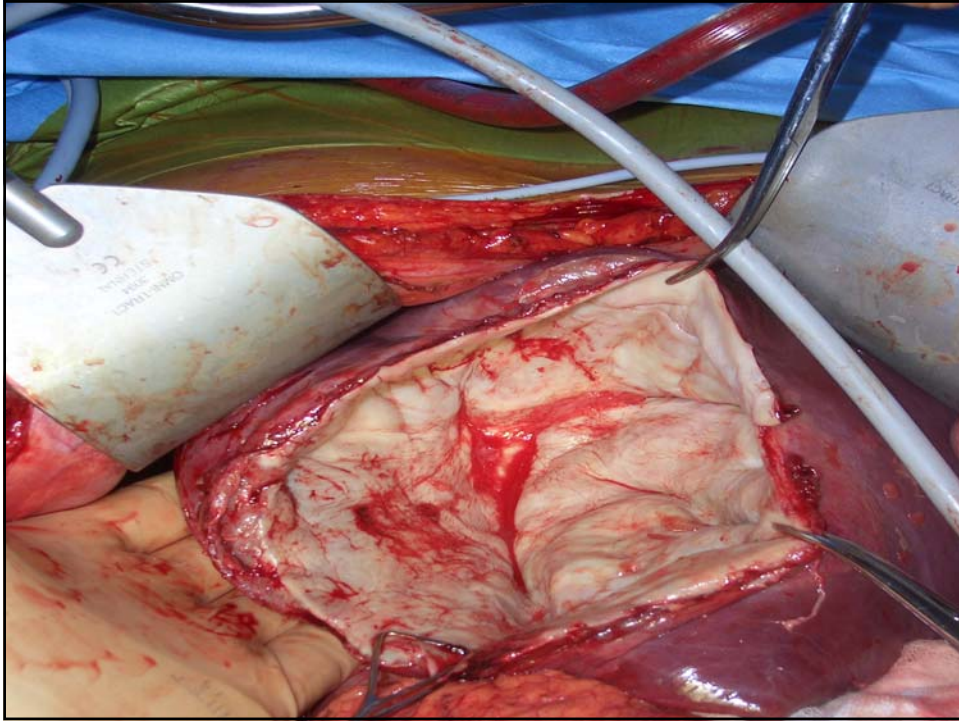
(more than one possible answer)

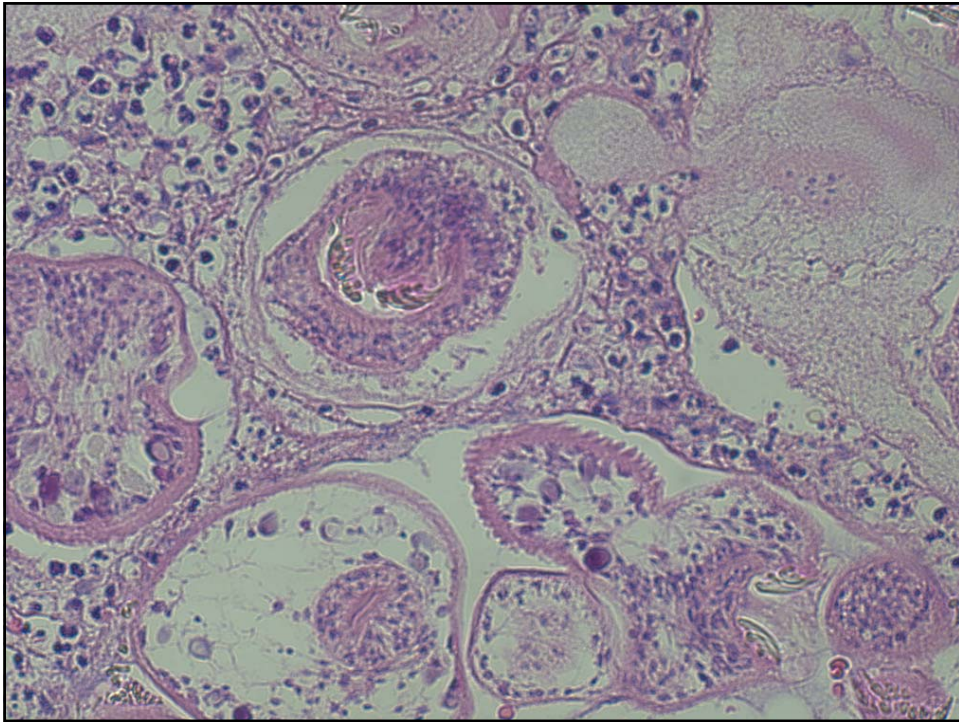
1. Serology for Echinococcus, more if positive
2. Hemodynamic surveillance
3. Emergency laparotomy with lavage
4. Laparotomy with cyst resection
5. Albendazole

## Treatment

- Hemodynamic surveillance on ICU
- Pre-operative Albendazole (Zentel®).
- Surgery, November 30th
- Post-operative Albendazole (Zentel®) for one month.







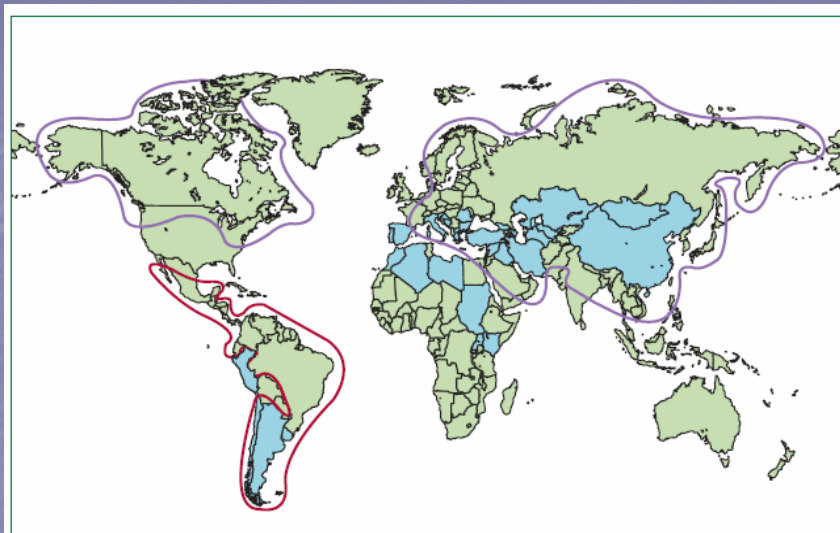
## Outcome

- No complications, discharged on day 12
- Albendazole for one month.
- 8 months later:
  - No relapse (Abdominal CT)

## Ruptured echinococcal cyst Complications

- Diffuse peritonitis (possibly lethal)
- Anaphylaxis
- Later: intra-abdominal disseminated cysts

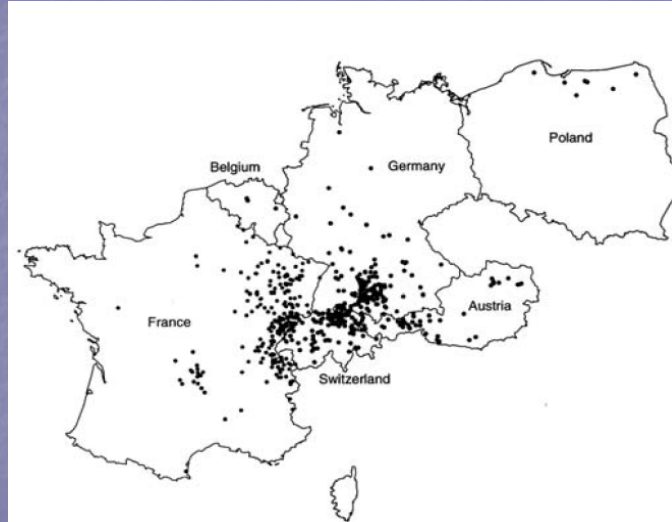
McManus DP. et al. *Lancet* 2003; 362 (9392):1295-1304.  
Smego RA et al. *CID* 2003; 37 (8):1073-1083.  
Beyrouti MI et al. *Presse Med.* 2004; 33(6):378-84.



**Figure 1:** Geographical distribution of cystic, alveolar, and polycystic echinococcosis (hydatid disease)  
Blue=countries endemic for cystic hydatid disease. Purple line=endemic areas for alveolar echinococcosis.  
Red line=areas where polycystic echinococcosis has been reported.

(Craig PS. *Lancet infect Dis* 2007; 7: 385-94)

## Human *alveolar* echinococcosis, Europe 1982-2000



(Kern P. *Emerg Infect Dis* 2003; 9: 343-9)

## Urban foxes and echinococcus

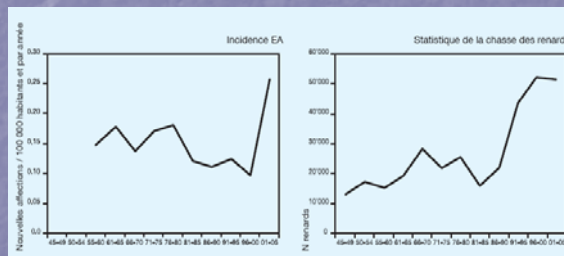


Upto 10 foxes/km<sup>2</sup> in Zürich city!

> 40% of the foxes in Geneva or Zürich are carriers of *E. multilocularis*

## Situation in Switzerland

*Echinococcus multilocularis*:  
0.26/100 000 inhabitants.



Deplazes P et al. Magazine de l'OVF 2007; (3): 2-4

By the way:  
the Valais blueberries are ripe ...

